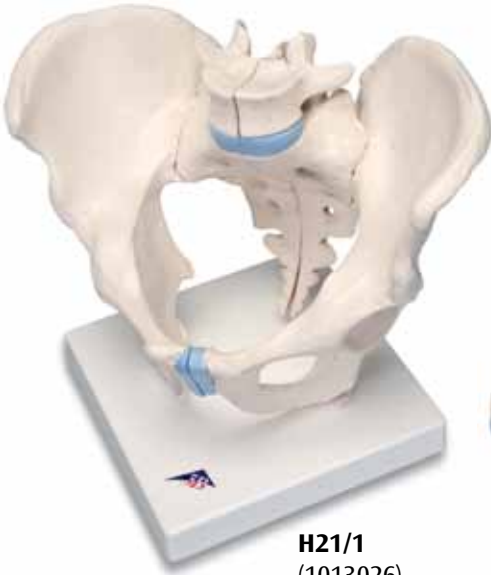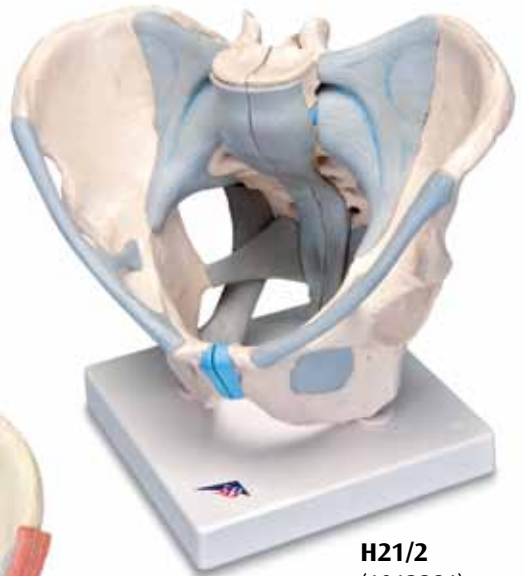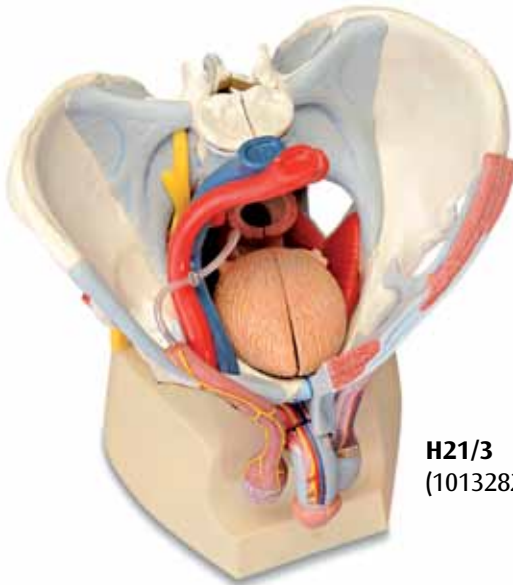




H21/1
(1013026)



H21/2
(1013281)



H21/3
(1013282)

H21/1
H21/2
H21/3

(1013026/1013281/1013282)

English

- 1 Lumbar vertebra [L V], superior articular process
- 2 Lumbar vertebra [L V], vertebral body
- 3 Lumbar vertebra [L V], costal process
- 4 Iliac crest
- 5 Anterior superior iliac spine
- 6 Iliac fossa
- 7 Sacro-iliac joint
- 8 Anterior inferior iliac spine
- 9 Body of ilium
- 10 Body of pubis
- 11 Acetabular fossa
- 12 Ischial spine
- 13 Ramus of ischium
- 14 Superior pubic ramus
- 15 Inferior pubic ramus
- 16 Interpubic disc; Interpubic fibrocartilage
- 17 Pecten pubis; Pectineal line
- 18 Obturator foramen
- 19 Anterior sacral foramina
- 20 Promontory
- 21 Ala of sacrum; Wing of sacrum
- 22 Lumbosacral joint, intervertebral disc
- 23 Lumbar vertebra [L V], inferior articular process
- 24 Sacrum, superior articular process
- 25 Ala of ilium; Wing of ilium
- 26 Intermediate sacral crest
- 27 Acetabular margin
- 28 Greater sciatic foramen
- 29 Ischial tuberosity
- 30 Coccygeal vertebra II
- 31 Sacral cornu; Sacral horn
- 32 Cauda equina
- 33 Posterior sacral foramina
- 34 Posterior superior iliac spine
- 35 Lumbar vertebra [L V], spinous process
- 36 Iliac tuberosity
- 37 Sacral vertebra II
- 38 Greater sciatic notch
- 39 Body of ischium
- 40 Lesser sciatic notch
- 41 (Posterior obturator tubercle)
- 42 Obturator groove
- 43 Arcuate line
- 44 Anterior longitudinal ligament
- 45 Iliolumbar ligament
- 46 Anterior sacro-iliac ligament
- 47 Inguinal ligament
- 48 Sacrotuberous ligament
- 49 Sacrospinous ligament
- 50 Obturator membrane
- 51 Supraspinous ligament
- 52 Posterior sacro-iliac ligament
- 53 Lateral sacrococcygeal ligament
- 54 Superficial posterior sacrococcygeal ligament
- 55 Deep posterior sacrococcygeal ligament
- 56 Lesser sciatic foramen
- 57 Obturator canal
- 58 Iliopectineal arch
- 59 Lacunar ligament
- 60 Vascular space
- 61 Muscular space
- 62 Abdominal aorta
- 63 Inferior vena cava
- 64 Lumbosacral trunk
- 65 Ductus deferens; Vas deferens
- 66 External iliac artery
- 67 External iliac vein
- 68 Cremaster
- 69 Anterior scrotal nerves
- 70 Dorsal nerve of penis
- 71 Glans penis
- 72 Dorsal artery of penis
- 73 Deep dorsal vein of penis
- 74 Tunica vaginalis [®]
- 75 Epididymis
- 76 Pampiniform plexus
- 77 Pyramidalis
- 78 Rectus abdominis
- 79 Urinary bladder
- 80 Transversus abdominis;
Transverse abdominal
- 81 Internal oblique
- 82 External oblique
- 83 Ureter
- 84 Rectum
- 85 Common iliac artery
- 86 External anal sphincter
- 87 Levator ani
- 88 Sciatic nerve
- 89 Pudendal nerve
- 90 Piriformis
- 91 Internal spermatic fascia
- 92 Femoral vein
- 93 Femoral artery
- 94 Bulbospongiosus
- 95 Obturator artery
- 96 Perineal nerves
- 97 Inferior anal nerves; Inferior rectal nerves
- 98 Superficial transverse perineal muscle
- 99 Deep transverse perineal muscle
- 100 Ischiocavernosus
- 101 Scrotum
- 102 Dartos fascia; Superficial fascia of scrotum
- 103 (Tendinous arch of levator ani)

- 104 Fundiform ligament of penis
- 105 Obturator internus
- 106 Testicular artery
- 107 Left testicular vein
- 108 Deep inguinal ring
- 109 Anus
- 110 Corpus spongiosum penis
- 111 External urethral orifice; External urinary meatus
- 112 Navicular fossa
- 113 Male urethra
- 114 Corpus cavernosum penis
- 115 Superficial inguinal ring
- 116 External spermatic fascia
- 117 Prostate
- 118 Sacral plexus
- 119 Seminal gland; Seminal vesicle
- 120 Internal iliac vein
- 121 Internal iliac artery
- 122 Internal urethral orifice; Internal urinary meatus
- 123 Rectal ampulla
- 124 Internal pudendal artery
- 125 Inferior gluteal artery
- 126 Superior gluteal artery
- 127 Iliolumbar artery



