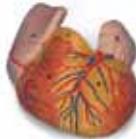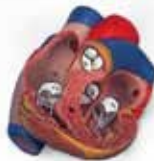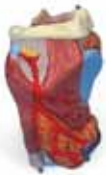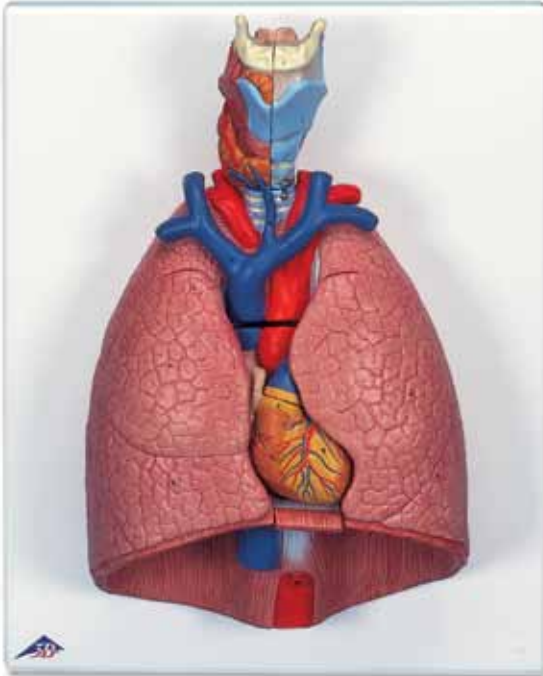


# MEDGUARD®

Professional Healthcare Supplies



*...going one step further*



## G15

(1000270)

Medguard Professional Healthcare

Tel: +353 (0) 1 835 2411

Email: [sales@medguard.ie](mailto:sales@medguard.ie)

Fax: 01 969 5009

Website: [www.medguard.ie](http://www.medguard.ie)

**Latin**

1 Os hyoideum

**A LARYNX**

- 2 Cartilago thyroidea
- 3 Cartilago cricoidea
- 4 Epiglottis
- 5 Cartilago arytenoidea
- 6 Membrana thyrohyoidea
- 7 M. thyrohyoideus
- 8 M. cricothyroideus
- 9 M. arytenoideus transversus
- 10 M. arytenoideus obliquus
- 11 M. cricoarytenoideus posterior
- 12 Ventriculus laryngis
- 13 A. laryngea superior
- 14 V. thyroidea inferior

**B GLANDULA THYROIDEA**

**C TRACHEA**

- 1 Bifurcatio tracheae
- 2 Bronchus principalis dexter
- 3 V. subclavia dextra
- 3a A. subclavia dextra
- 4 A. carotis communis dextra
- 5 V. jugularis interna dextra
- 6 V. brachiocephalica dextra
- 7 Truncus brachiocephalicus
- 8 A. pulmonalis

**D OESOPHAGUS**

**E PULMO**

**Pulmo dexter**

- a Lobus superior
- b Lobus medius
- c Lobus inferior

**Pulmo sinister**

- d Lobus superior
- e Lobus inferior

**F COR**

- 9 Ventriculus sinister
- 10 Pars ascendens aortae
- 11 Valva aortae
- 13 Atrium sinistrum
- 14 Auricula sinistra
- 15 Valva atrioventricularis sinistra  
[Valva mitralis]
- 16 Ventriculus dexter
- 17 Truncus pulmonalis
- 18 Valva trunci pulmonalis

19 Atrium dextrum

20 Auricula dextra

21 V. cava superior

22 V. cava inferior

23 Valva atrioventricularis dextra  
[Valva tricuspidalis]

24 Vv. pulmonales

**G DIAPHRAGMA**



# Lung Model with larynx, 7-part

English

1 Hyoid bone

## A LARYNX

- 2 Thyroid cartilage
- 3 Cricoid cartilage
- 4 Epiglottis
- 5 Arytenoid cartilage
- 6 Thyrohyoid membrane
- 7 Thyrohyoid
- 8 Cricothyroid
- 9 Transverse arytenoid
- 10 Oblique arytenoid
- 11 Posterior crico-arytenoid
- 12 Laryngeal ventricle
- 13 Superior laryngeal artery
- 14 Inferior thyroid vein

## B THYROID GLAND

## C TRACHEA

- 1 Tracheal bifurcation
- 2 Right main bronchus
- 3 Right subclavian vein
- 3a Right subclavian artery
- 4 Right common carotid artery
- 5 Right internal jugular vein
- 6 Right brachiocephalic vein
- 7 Brachiocephalic trunk
- 8 Pulmonary artery

## D ESOPHAGUS

## E LUNG

### Right lung

- a Superior lobe
- b Middle lobe
- c Inferior lobe

### Left lung

- d Superior lobe
- e Inferior lobe

## F HEART

- 9 Left ventricle
- 10 Ascending aorta
- 11 Aortic valve
- 13 Left atrium
- 14 Left auricle
- 15 Mitral valve [Left atrioventricular valve]
- 16 Right ventricle
- 17 Pulmonary trunk
- 18 Pulmonary valve
- 19 Right atrium

20 Right auricle

21 Superior vena cava

22 Inferior vena cava

23 Tricuspid valve [Right atrioventricular valve]

24 Pulmonary veins

## G DIAPHRAGM

